

Histology and Immunohistochemistry Core Unit



Lydia Sánchez

Unit Head

Lydia Sánchez was born in Toledo (Spain) and received her Degree in Biological Sciences from the *Universidad Complutense* in Madrid in 1985. In 1987 she was appointed as Fellow in the Department of Genetics, the *Hospital Virgen de la Salud*, Toledo, where she began to work with molecular genetics and cytogenetic techniques.

From 1990-1995, Lydia worked on the immunophenotypic characterisation of lymphomas & leukaemias, and minimal residual disease (MDR). Several clone-specific probes were produced to follow-up and detect MDR in B-ALL patients.

From 1996-2000, she set up immunohistochemistry procedures and coordinated the first Spanish Agency of Quality Control in Immunohistochemistry (ACCIHQ).

She joined the CNIO in February 2000 as Head of the Histology and Immunohistochemistry Core Unit, setting up the tissue microarray technology as a high-throughput tool in cancer research. From 2001-2010 she has been involved in several educational programmes and workshops.

She is consultant for several Immunohistochemistry Quality Control Programmes of the *Sociedad Española de Anatomía Patológica* (SEAP) and has contributed to over 50 articles published in renowned international publications.

Summary

The Unit was established in 2001 as a Core Unit for histopathology analysis, providing the most up-dated technologies within the field for both research and clinical aspects in order to contribute to a better diagnosis as well as facilitate the translation of basic discoveries into clinical applications.

We are committed to providing a high quality range of services including histopathology, immunohistochemistry, immunofluorescence, *in situ* hybridisation, tissue microarray, laser microdissection, image analysis and hands-on training, consulting and technical support.

The laboratory provides all the necessary equipment necessary to carry out most processes in an automated fashion. Currently, we have three platforms (from DAKO, Leica and Roche) for immunohistochemical and *in situ* hybridisation techniques. We also offer more than 750 primary antibodies, cell line paraffin embedded blocks, a tissue microarray bank and several visualisation systems. The Unit has ISO 9001 Certification and participates in External Quality Control Scheme: CECP from SEAP.

Main Objectives

- Provide high quality histopathology services, including tissue microarray production; develop and implement new technologies and protocols
- Characterise new and interesting antibodies
- Establish a gold standard chromogenic *in situ* hybridisation (CISH) procedure to detect miRNAs
- To obtain ISO15189 accreditation for clinical laboratories



Technicians: María J. Campillo, Ana Díez, Enrique Ochoa (until April), Raquel Pajares and Zaira Vega.

Highlights

Customised protocols for multiple immunostaining using antibody combinations (antibody COCKTAILS) – more than 10 antibody COCKTAILS are currently in use.

Colorimetric and morphometric analysis using a high throughput automated image analysis system (ARIOL) for tissue microarrays and antibody expression profile analysis.

SISH (silver *in situ* hybridisation) implementation: as a new tool for the detection of gene amplifications, deletions and translocations simultaneously with tissue morphology in bright-field microscopy.

Development of protocols combining double chromogenic *in situ* hybridisation (CISH™), SISH and immunohistochemistry.

Additionally the Unit has set up a protocol to visualise microRNAs (miRNAs) using chromogenic *in situ* hybridisation.

Laser microdissection (LMD) on double immunofluorescence has been implemented in paraffin and frozen samples with high quality DNA to use in comparative genomic hybridisation (CGH) and microRNA analysis.

The Unit is equipped with: a Palm Microlaser Microdissector; Dot Slide & ARIOL: slide digitalisation and quantification system; DAKO Autostainer plus, Leica Bond MAX & Roche Benchmark ULTRA platforms; and Beecher ATA-27 Tissue arrayer.

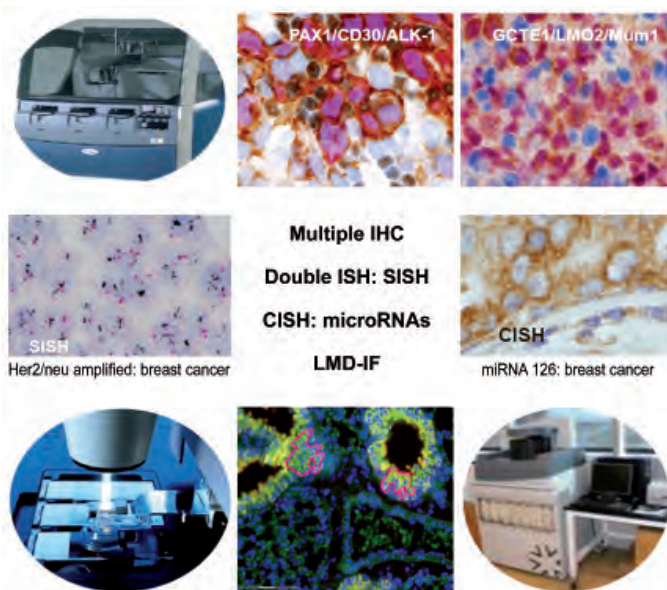


Figure: Major highlights performed by the Unit. Upper panels: multiple immunohistochemistry on antibody cocktails PAX1/CD30/ALK1 and GCET1/LMO2/ Mum1. Middle panels: SISH: Her2/neu amplified in breast cancer; CISH to detect miRNA 126. Lower panels: laser microdissection on double immunofluorescence.

The Unit is involved in the following research activities: antibody characterisation for utility in diagnosis, prognosis or therapy, using tissue microarrays and image analysis quantification technology; multiple staining using a combination of different technologies: IHC-IF-CISH/SISH; and tissue microarray production.

Collaborative activities: Masters in Molecular Oncology and External Quality Control Scheme (SEAP) participation.

Certification: External Quality Control Scheme: the Spanish Society of Pathological Anatomy (SEAP).

Publications

Herreros B, Rodríguez-Pinilla SM, Pajares R, Martínez-González MA, Ramos R, Muñoz I, Montes-Moreno S, Lozano M, Sánchez-Verde L, Roncador G, Sánchez-Beato M, de Otazu RD, Pérez-Guillermo M, Mestre MJ, Bellas C, Piris MA (2010). Proliferation centers in chronic lymphocytic leukemia: the niche where NF-kappaB activation takes place. *Leukemia* 24, 872-876.

Wahlén BE, Aggarwal M, Montes-Moreno S, Gonzalez LF, Roncador G, Sanchez-Verde L, Christensson B, Sander B, Kimby E (2010). A unifying microenvironment model in follicular lymphoma: outcome is predicted by programmed death-1--positive, regulatory, cytotoxic, and helper T cells and macrophages. *Clin Cancer Res* 16, 637-650.

Castillo SD, Angulo B, Suarez-Gauthier A, Melchor L, Medina PP, Sanchez-Verde L, Torres-Lanzas J, Pita G, Benitez J, Sanchez-Cespedes M. (2010). Gene amplification of the transcription factor DP1 and *CTNND1* in human lung cancer. *J Pathol* 222, 89-98.

Montes-Moreno S, et al. (2010). Aggressive large B-cell lymphoma with plasma cell differentiation: immunohistochemical characterization of plasmablastic lymphoma and diffuse large B-cell lymphoma with partial plasmablastic phenotype. *Haematologica* 95, 1342-1349.

Rodríguez-Pinilla SM, et al. (2010). EBV-associated Cutaneous NK/T-cell Lymphoma: review of a series of 14 cases from Peru in children and young adults. *Am J Surg Pathol* 34, 1773-1782.

Montes-Moreno S, et al. (2010). Intrafollicular neoplasia/*in situ* follicular lymphoma: review of a series of 13 cases. *Histopathology* 56, 658-662.

Cano I, et al. (2010). Nodular lymphocyte-predominant Hodgkin lymphoma and T cell histiocyte-rich large B cell lymphoma: diagnosis in two monozygotic twins. *Histopathology* 57, 159-162.